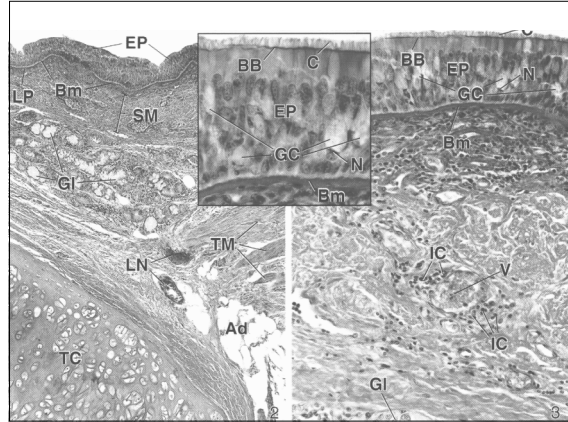
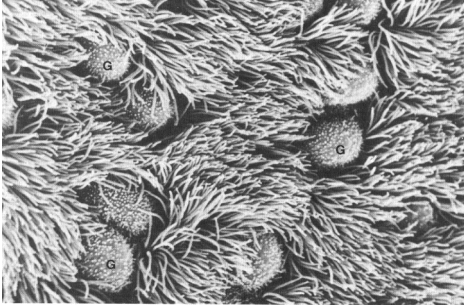


## RESPIRATORY

Many images found in the following material are copyright-protected and are used in conformance with the fair use provisions of the U.S. copyright law. Distribution is intended for students officially registered for this class.



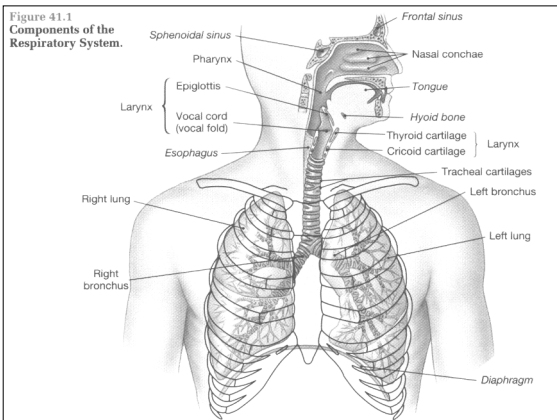
### I. General Information

#### A. Physiological properties

1. what is meant by the term "respiration"?
2. what is meant by the term "ventilation"?
  - a) inspiration (breathing in)
  - b) expiration (breathing out)

#### B. What are the anatomical passageways that air travels through?

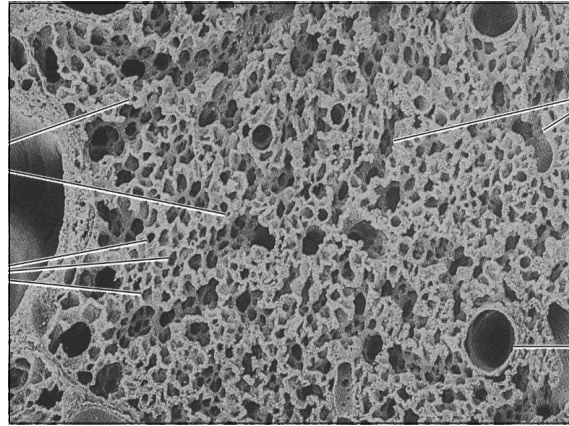
1. nasal chambers
  - a) anterior nares
  - b) posterior nares
  - c) nasal cavities
  - d) nasal septum
  - e) turbinate bones
  - f) vascular plexus
  - g) olfactory epithelium
  - h) pseudostratified epithelium



2. paranasal sinuses
3. nasopharynx
4. larynx
5. trachea
6. bronchi
  - a) primary
  - b) secondary and others
7. bronchioles

**C. What are the anatomical sites of gas exchange?**

1. respiratory bronchioles
2. alveolar ducts
3. alveolar sacs
4. alveoli



**II. What is the histology of the major "conduction" airways?**

**A. What are the various histological parts of the trachea?**

1. what is its length and diameter?
2. what is meant by the term "mucosa"?
  - a) pseudostratified ciliated columnar epithelium
  - b) lamina propria (loose connective tissue)
3. how is hyaline cartilage arranged in the wall of the trachea?
4. is there any smooth muscle in the wall of the trachea? (trachealis)
5. are there any mucous-secreting glands in the wall of the trachea?
  - a) tracheobronchial glands
  - b) where precisely are they located?
6. the "adventitia"

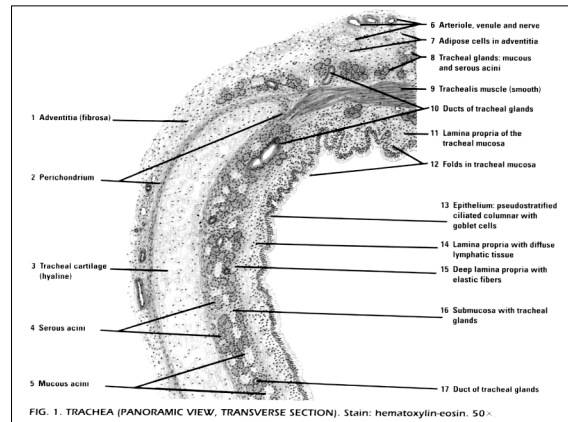
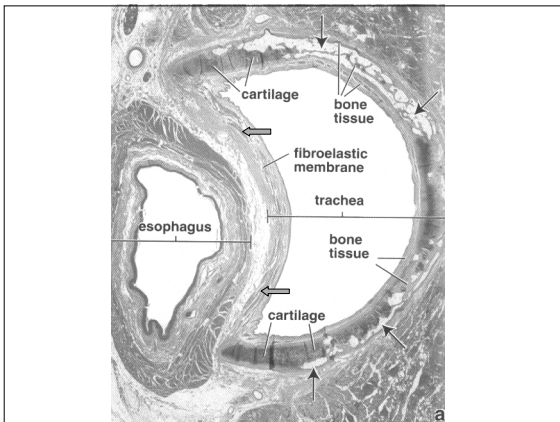
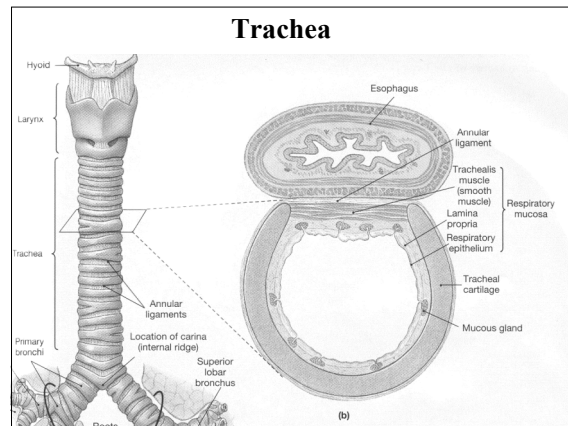
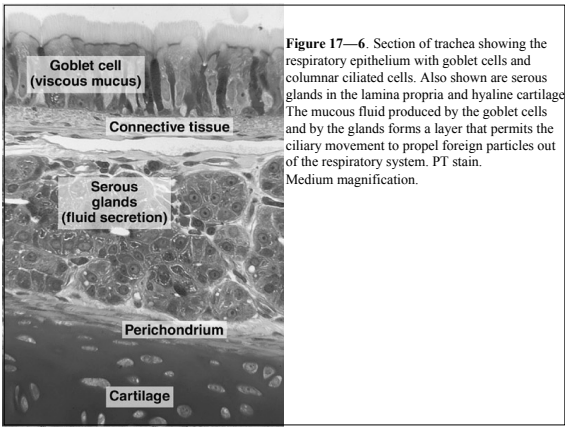
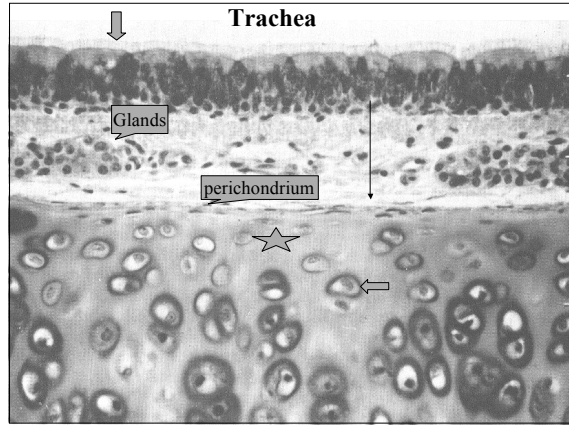
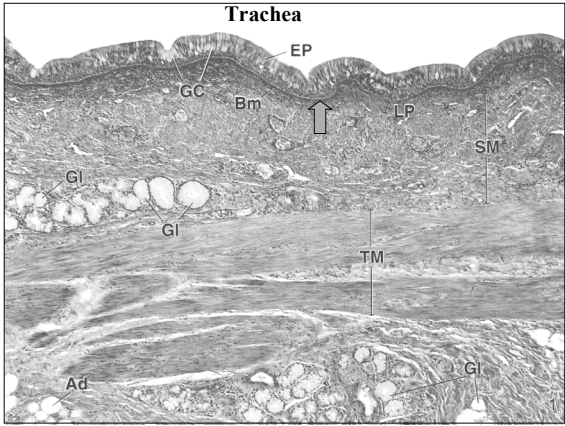
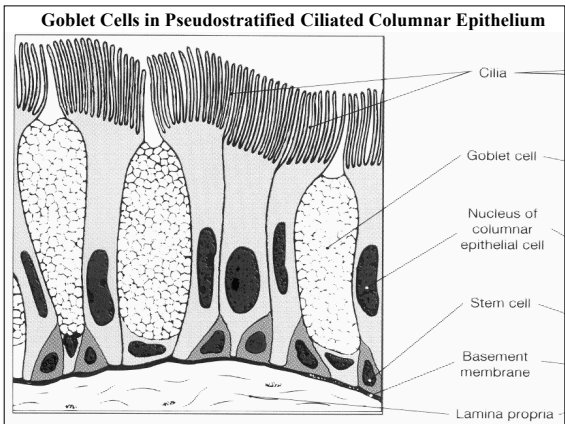
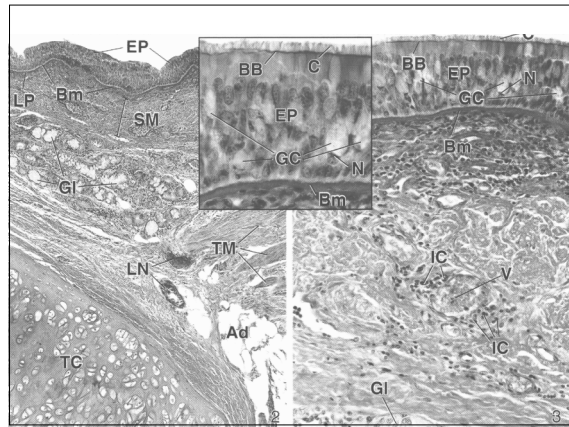


FIG. 1. TRACHEA (PANORAMIC VIEW, TRANSVERSE SECTION). Stain: hematoxylin-eosin. 50x



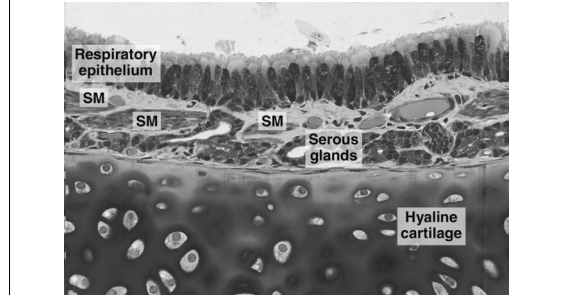
**Figure 17—6.** Section of trachea showing the respiratory epithelium with goblet cells and columnar ciliated cells. Also shown are serous glands in the lamina propria and hyaline cartilage. The mucous fluid produced by the goblet cells and by the glands forms a layer that permits the ciliary movement to propel foreign particles out of the respiratory system. PT stain. Medium magnification.

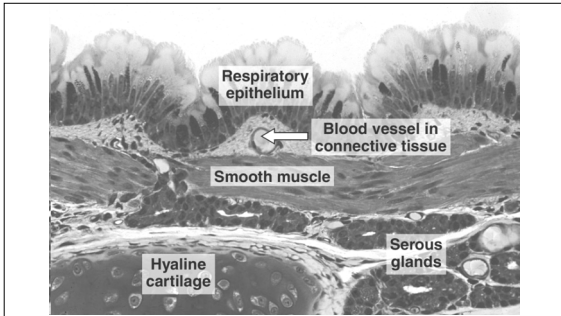


**B. The primary bronchi**

**Fig 17-8**

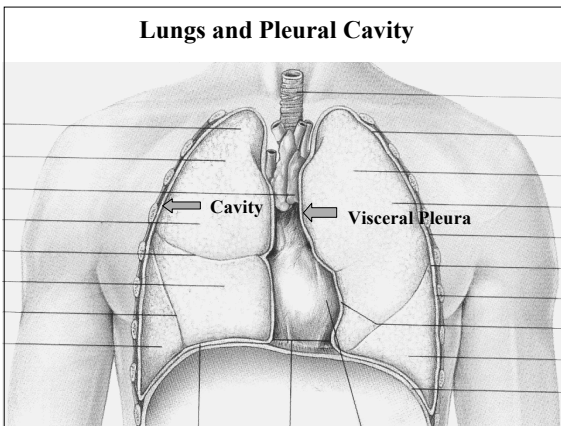
1. are they in the lung or in the mediastinum?
2. how is hyaline cartilage arranged in the bronchi?
3. are there any glands in the wall of bronchi?



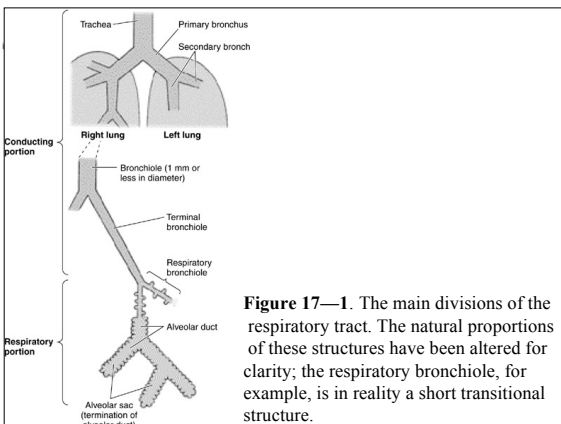


**Figure 17—9.** Large bronchus. Note the distinct layer of smooth muscle that influences the flux of air in the respiratory system. PT stain. Medium magnification.

- C. Inside of the lung**
- where is the mediastinum?
  - what is the arrangement of the pleura?
    - visceral pleura  
--on the lung surface
    - parietal pleura  
--attached to chest wall and diaphragm
    - the pleural cavity
  - how many secondary bronchi are found in human lungs?
    - right lung (3)
    - left lung (2)
    - how many lobes are found in each lung?



- the tertiary bronchi
  - what is so very clinically important about tertiary bronchi?
  - the bronchopulmonary segments of the lung
- how many generations of branching bronchi are found? (10)
- what is formed during branching of the airways when hyaline cartilage disappears from the wall of the airway?
  - bronchioles
  - terminal bronchioles
    - (1) creates the "lobular" structure of the lung
    - (2) divide into respiratory bronchioles
- what are the names of the respiratory passageways?



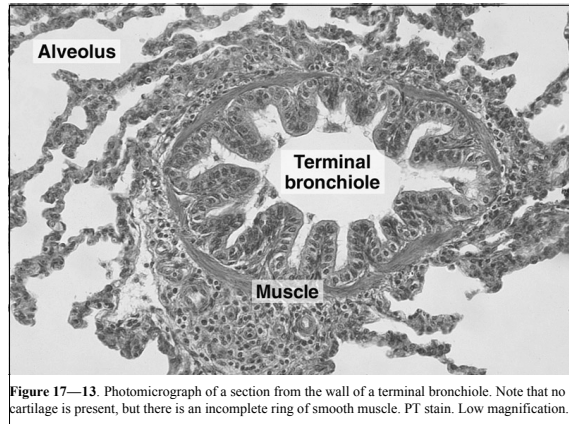
**Figure 17—1.** The main divisions of the respiratory tract. The natural proportions of these structures have been altered for clarity; the respiratory bronchiole, for example, is in reality a short transitional structure.

**TABLE 18.1. Divisions of the Bronchial Tree and Summary of Its Histologic Features**

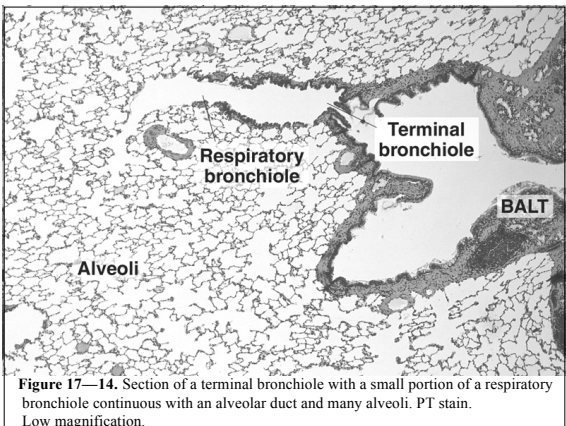
	epithelium	goblet cells	ciliated cells	glands	hyaline cartilage	smooth muscle	elastic fibers
trachea	present	present	present	present	present	present	present
main bronchus	present	present	present	present	present	present	present
lobar bronchus	present	present	present	present	present	present	present
segmental bronchus	present	present	present	present	present	present	present
terminal bronchiole	present	absent	absent	absent	absent	present	absent
respiratory bronchioles	present	absent	absent	absent	absent	absent	absent
alveolar duct	absent	absent	absent	absent	absent	absent	absent
alveolar sacs	absent	absent	absent	absent	absent	absent	absent
alveoli	absent	absent	absent	absent	absent	absent	absent

**D. What is the histological structure of bronchioles?**

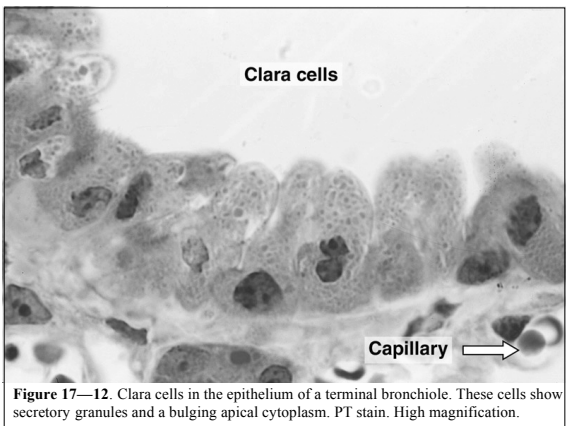
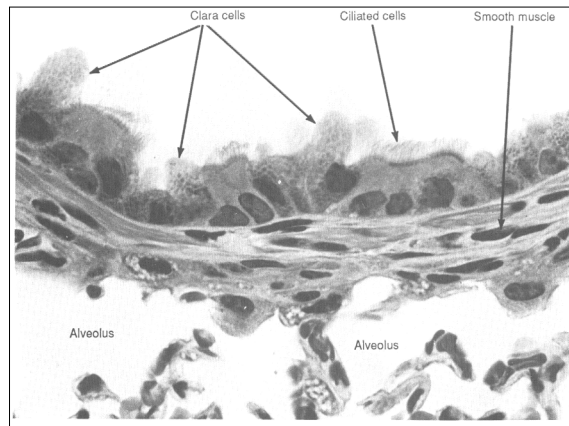
1. how big are they?
2. is there any hyaline cartilage in their walls?
3. how important is the smooth muscle in the wall of bronchioles?
4. what epithelium is found in the wall of bronchioles?
  - a) ciliated columnar
  - b) goblet cells disappear
  - c) ciliated cuboidal
  - d) what are "Clara cells"?



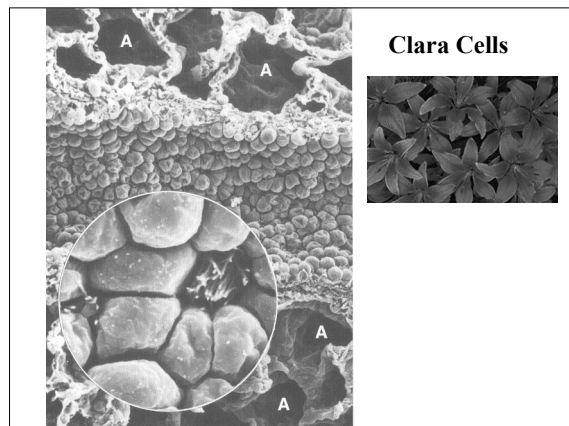
**Figure 17—13.** Photomicrograph of a section from the wall of a terminal bronchiole. Note that no cartilage is present, but there is an incomplete ring of smooth muscle. PT stain. Low magnification.



**Figure 17—14.** Section of a terminal bronchiole with a small portion of a respiratory bronchiole continuous with an alveolar duct and many alveoli. PT stain. Low magnification.



**Figure 17—12.** Clara cells in the epithelium of a terminal bronchiole. These cells show secretory granules and a bulging apical cytoplasm. PT stain. High magnification.



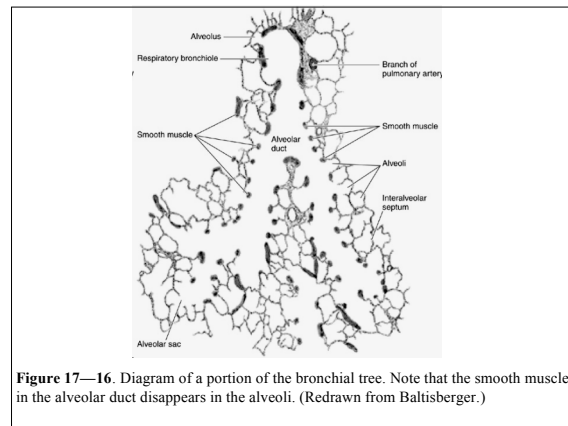
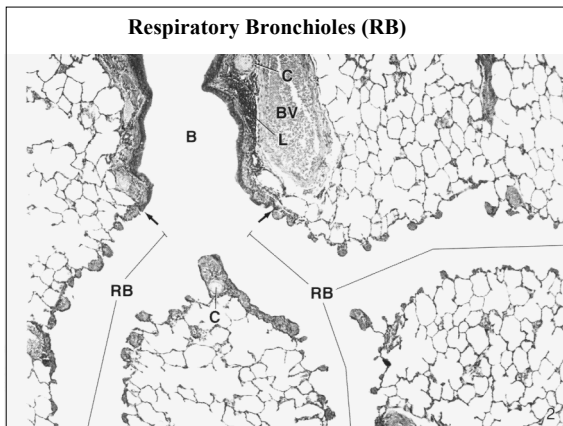
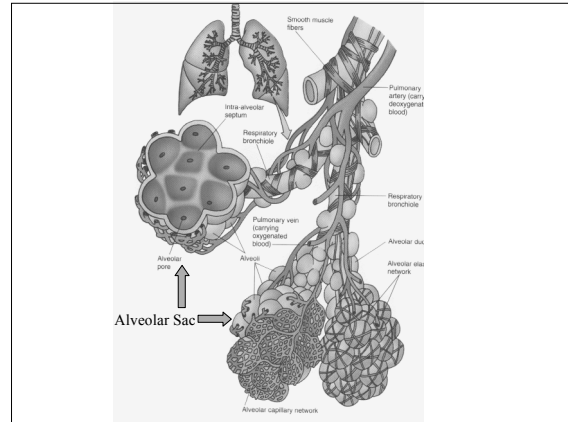
**III. What is the histological structure of the "respiratory" passageways?**

**A. What are the so-called "respiratory bronchioles"?**

1. cuboidal epithelium (any cilia?)
2. is there any simple squamous epithelium in these passageways?
3. are there any alveoli attached to respiratory bronchioles?

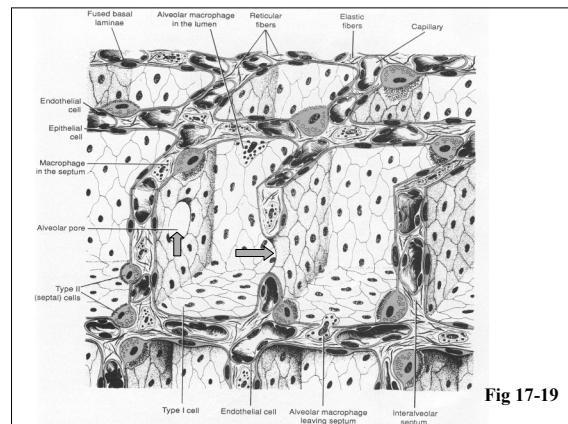
**B. What is the arrangement of the alveolar ducts?**

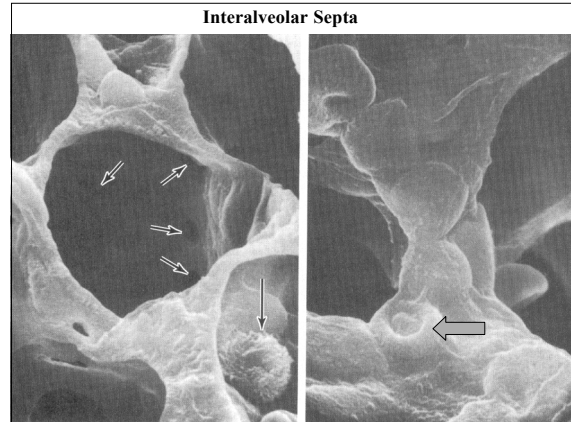
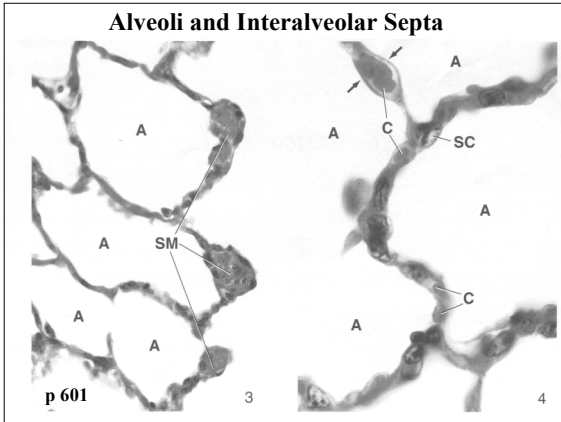
1. is there any simple cuboidal epithelium?
2. how is the simple squamous epithelium arranged?
3. what is the arrangement of alveoli along the alveolar ducts?
4. what are alveolar sacs
5. what is so important about elastic fibers around alveoli?



**C. What is found in interalveolar septa?**

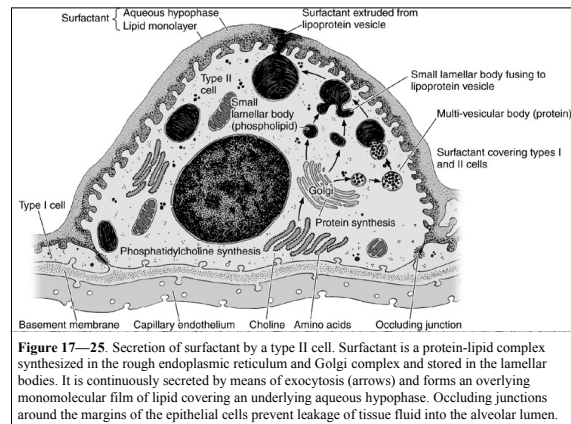
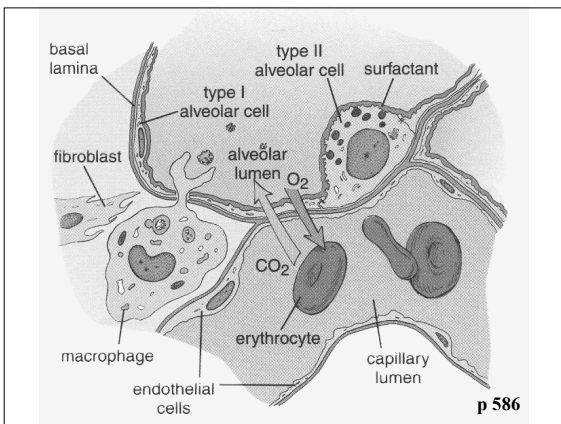
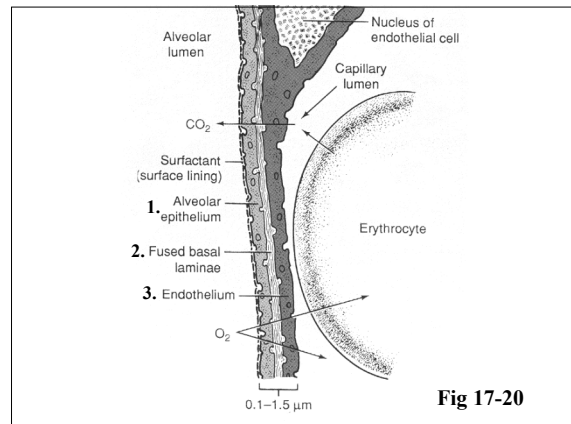
1. the tissue space
2. capillaries
3. what is the arrangement of basal laminae around the alveoli
4. elastic and reticular fibers
5. what is a pore of Kohn?





**D. What is the anatomy of the blood-air-barrier? DRAW**

1. alveolar lining cells
  - a) type I alveolar cells (simple squamous)
  - b) type II alveolar cells
    - (1) what is the all important secretion from type II cells?
    - (2) when do they form in the human body?
    - (3) what happens when they are missing?
    - (4) when do we find "too many" of them?
2. the endothelium of alveolar capillaries
  - a) "fused" basal laminae
  - b) are there any important secretions from these endothelial cells?



**IV. What defense mechanisms are found along the airways?**

**A. Nasal hairs (should be manicured properly)** 😊

**B. Secretory IgA**

**C. The famous mucociliary escalator**

1. pseudostratified epithelium
2. goblet cells
3. tracheobronchial glands
4. ciliated cells

**D. Alveolar macrophages**

1. how do these cells work?
2. Mycobacterium tuberculosis

